

Enlargement of the narrow aortic annulus: valid, but not much sought-after technique

Pavel Žáček, Jan Vojáček, Jan Dominik, Jan Harrer

Department of Cardiac Surgery, Charles University in Prague, Faculty of Medicine in Hradec Králové and Faculty Hospital Hradec Králové, Czech Republic

Adresa: Doc. MUDr. Pavel Žáček, Ph.D., Kardiologická klinika LF UK a FN Hradec Králové, Šimkova 870, 500 38 Hradec Králové, e-mail: zacek@fnhk.cz

Implantation of sufficiently large artificial valve is one of the key imperatives for a surgeon replacing the diseased native heart valve. This may be a particular problem in some patients with significantly narrow aortic annulus; typically patients of small stature, women or Asians. Inadequate – smaller than needed – size of the valve implant may lead to patient-prosthesis mismatch with negative impact on unburdening of the left ventricle and overall outcome of the valve surgery. Despite the fact that issue of patient-prosthesis mismatch has remained to be controversial in view of its real clinical prevalence and significance both industry and surgeons have addressed this problem in various ways. Valve manufacturers have developed heart valves with optimized hemodynamic profile and technique of implantation. Nevertheless, it may occur that even the smallest available manufactured valve fails to be implanted or its size is in striking contrast to the estimated hemodynamic requirements of a patient with large body size. In such case, surgical enlargement of the narrow aortic annulus is necessary.

Enlargement of the aortic annulus means always its interruption and extension of its circumference by a patch. Such procedure in high-pressure blood compartment, close vicinity of the aortico-mitral continuity and the left atrium and altered calcium-infiltrated tissue of the annulus is instinctively considered to carry higher surgical risks. Especially difficult is the situation in case of simultaneous mitral valve replacement where only a narrow bridge of tissue remains in front of the already implanted mitral prosthesis.

With regards to anatomic interrelations, three classical concepts of annulus enlargement were introduced in routine practice (Figure 1). In 1970 Nicks described a posterior approach across the aortic ring as far the origin of the mitral valve¹ (Figure 2). Manougian (1979) proposed extension of the oblique aortotomy into the commissure between the left and non-coronary sinus and incision of the anterior mitral leaflet and left atrium.² A patch from

autologous pericardium, Dacron or PTFE is interposed in the gap (Figure 3). A heart valve one or two sizes larger is then implanted subcoronary in the area of the left and right coronary sinus whereas in the area of enlargement the sutures are passed through the patch in a horizontal line with pledgets on its external side. To avoid potential impairment of mitral valve pliability in the long term when Dacron was used for a patch, as originally described by Manougian, Molina published excellent results with his double-patch technique.³ A thin Gore-Tex (W. L. Gore, Flagstaff, AZ) with a pore size of 22 µm used to fill the gap in the mitral valve retained its pliability and mobility after 13 years of follow-up.

Different technique of narrow aortic annulus enlargement was described in 1975 simultaneously by Konno, Rastan and Koncz.^{4,5} Their technique, however, is prima-

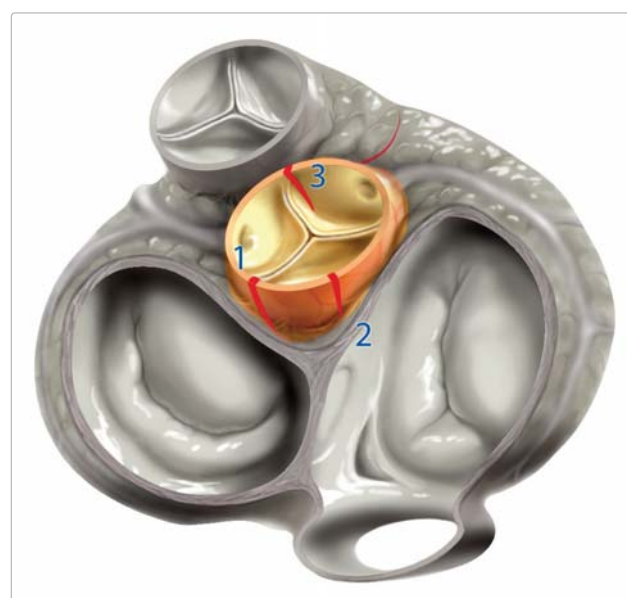

Figure 1 A schematic depiction of the three approaches to the enlargement of aortic annulus: 1 – Manougian, 2 – Nicks, 3 – Konno

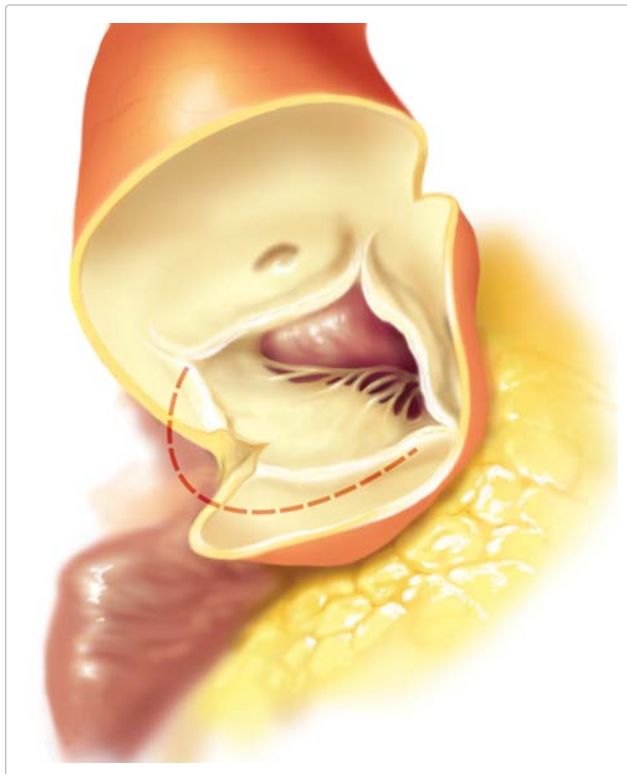


Figure 2 Enlargement of the aortic annulus according to Nicks: incision of the aortic annulus is directed towards the nadir of the non-coronary cusp but does not enter the anterior mitral leaflet

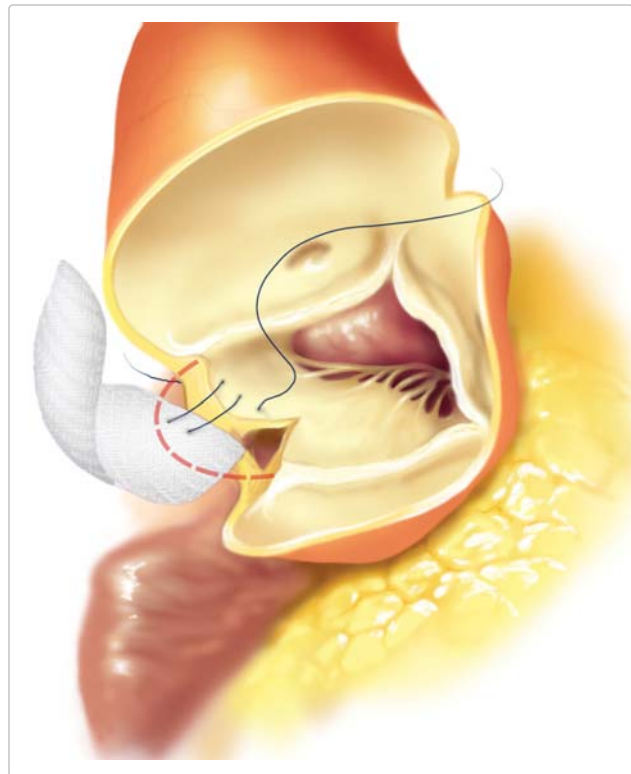


Figure 3 In Manougian technique the incision is carried through the commissure between the left and non-coronary cusp and extends into the anterior mitral leaflet

rily intended for a complex procedure in case of tunnel fibromuscular subaortic stenosis. Right ventriculotomy beneath the pulmonary valve is carried towards the aortic annulus which is incised in the commissure between the left and right coronary cusp and down in the ventricular septum. A wide Dacron patch sewn in the septum relieves the subvalvular stenosis and in case of hypoplastic aortic annulus it is sutured across the annulus up in the wall of the aortic root (Figure 4).

In our practice, surgical enlargement of the aortic annulus in the era of current optimized valve prostheses is reserved for infrequent situation of serious implantation problem. We prefer incision in the commissure between the left and non-coronary cusp (Manougian-alike) because this

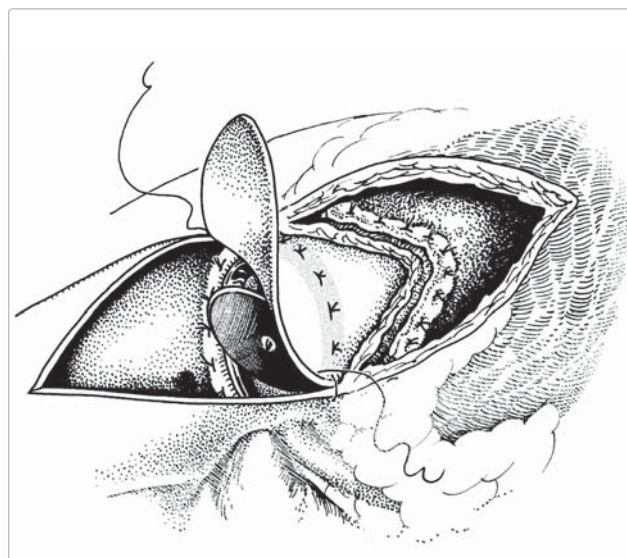


Figure 4 Konno technique with incision through the right ventricular outflow tract and ventricular septum

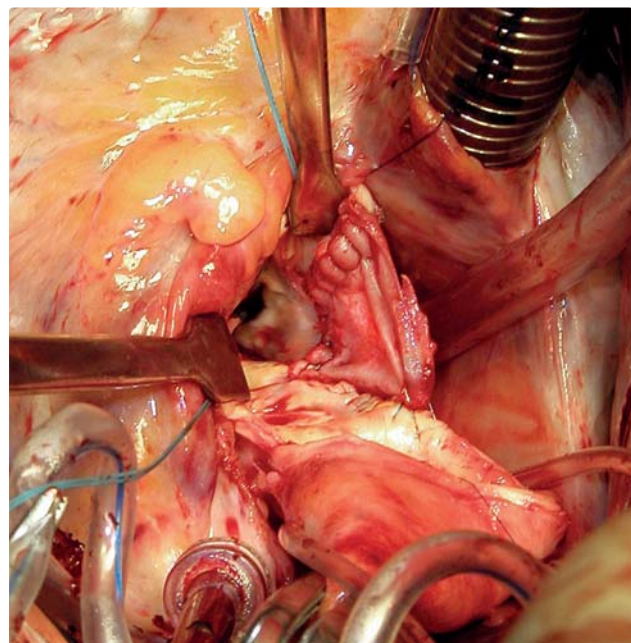


Figure 5 Surgical technique: a patch from the glutaraldehyde-treated autologous pericardium is sewn into the incision carried through the commissure between the left and non-coronary cusp

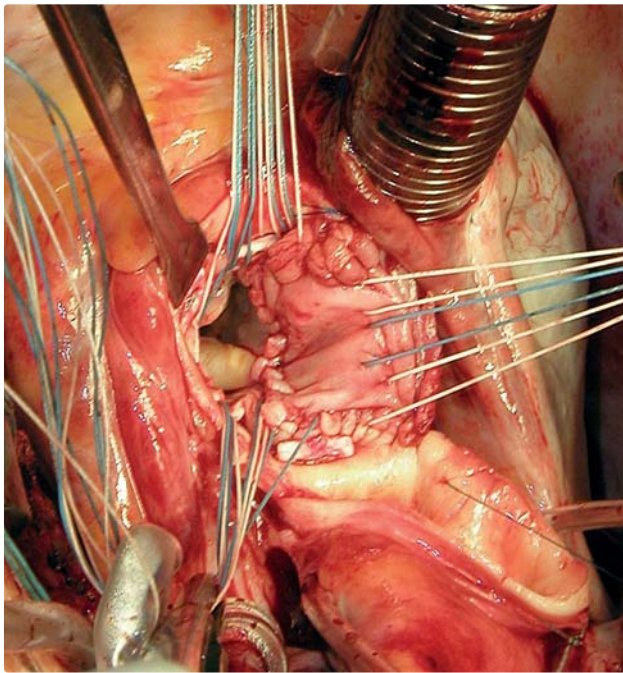


Figure 6 The patch enlarges the annular circumference for placement of the implantation sutures

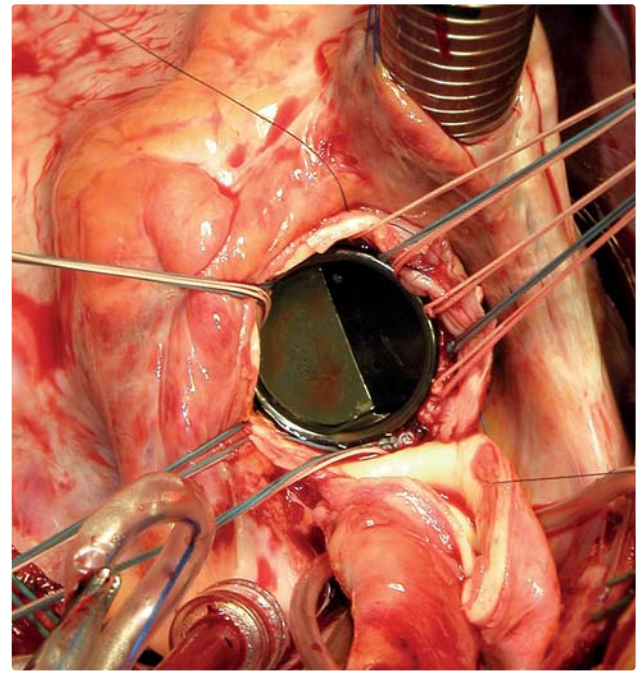


Figure 7 The patch-enlarged aortic annulus can accommodate a 1–2 sizes bigger valve

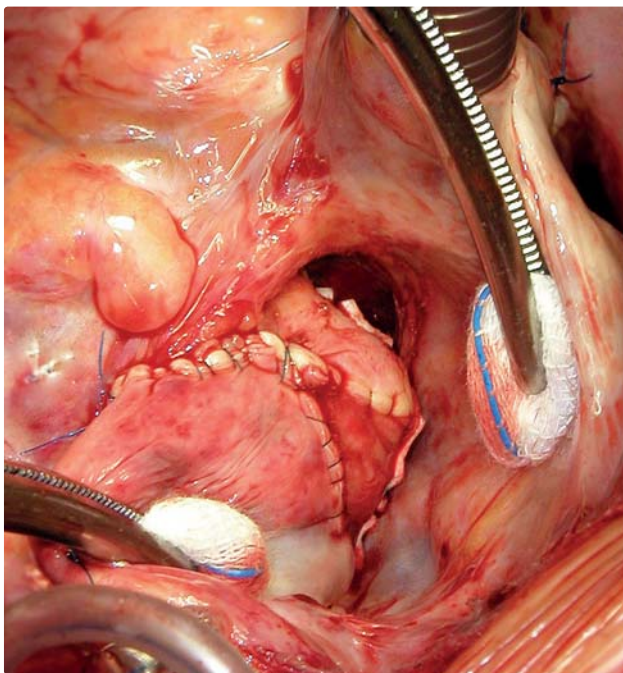


Figure 8 During closure the drop-shaped pericardial patch is incorporated in the aortotomy suture

prominent triangular area offers extra extent of tissue and therefore allows for sufficient incision without entering the anterior mitral leaflet (contrariwise to Manouguian). The gap is filled preferably with autologous glutaraldehyd-treated pericardium. The procedure is illustrated in surgical steps (Figures 5–8).

References

1. Nicks R, Cartmill T, Bernstein L. Hypoplasia of the aortic root. The problem of aortic valve replacement. *Thorax* 1970;25:339–346.
2. Manouguian S, Seybold-Epting W. Patch enlargement of the aortic valve ring by extending the aortic incision into the anterior mitral leaflet. New operative technique. *J Thorac Cardiovasc Surg* 1979;78:402–412.
3. Molina JE. Enlargement of the aortic annulus using a double-patch technique: a safe and effective method. *Ann Thorac Surg* 2002;73:667–670.
4. Konno S, Imai Y, Iida Y, Nakajima M, Tatsuno K. A new method for prosthetic valve replacement in congenital aortic stenosis associated with hypoplasia of the aortic valve ring. *J Thorac Cardiovasc Surg* 1975;70:909–917.
5. Rastan H, Koncz J. [Plastic enlargement of the left ventricular outflow tract. A new operative method]. *Thoraxchir Vask Chir* 1975;23:169–175.

Došlo do redakce: 30. 3. 2011

Přijato: 27. 5. 2011